

Viral encephalitis associated with COVID-19 and following COVID-19 vaccination: a review of the literature and three cases.



Nadia Mahmoud Tawfiq Jebril^{1,2}, Ali Abbas Hashim Al-Musawi^{3,4}, Charles Braungardt²

¹Department of Biology, College of Sciences for Women, University of Babylon, Iraq;

² School of Biological and Marine Sciences, University of Plymouth, Drake's Circus, Plymouth PL4 8AA, UK

³Consultant Neurosurgeon FRCS Glasg, FRCSED, FRCSE, FACS, FIBMS, University of Babylon, Babylon, Iraq

⁴Department of Neurosurgery, Hammurabi College of Medicine, University of Babylon, Babylon, Iraq

ARTICLE INFO

Received: 25 / 03 / 2023

Accepted: 19 / 06 / 2023

Available online: 10 / 12 / 2023

DOI: [10.37652/juaps.2023.139243.1049](https://doi.org/10.37652/juaps.2023.139243.1049)

Keywords:

COVID-19, nervous system, encephalitis, human coronaviruses, neuroinvasion, respiratory viral infection, SARS-CoV-2.

Copyright©Authors, 2022, College of Sciences, University of Anbar. This is an open-access article under the CC BY 4.0 license (<http://creativecommons.org/licenses/by/4.0/>).



ABSTRACT

Severe acute respiratory syndrome-related coronavirus (SARS-CoV-2) infects the human upper respiratory, causing coronavirus disease 2019 (COVID-19) with symptoms of acute respiratory distress syndrome (ARDS). However, in susceptible populations, such as immune-compromised individuals and the elderly, the symptoms develop into more severe diseases (e.g., pneumonia). Data reported in neurological studies have also confirmed that SARS-CoV-2 has neuroinvasive capacities, as it could be spread from the respiratory tract to the nervous system (NS), causing encephalitis. Compared to neuroinvasive human coronaviruses, SARS-CoV-2 may damage the nervous system, causing neurological diseases. Opportunistic human SARS-CoV-2 pathogens could be connected with the activating or the exacerbation of several neurological complaints whose etiology leftovers ailing unstated. In this review, details about human coronaviruses that have been linked to the possibility of developing a disease of the nervous system were illustrated. Three cases of COVID-19 patients who had viral encephalitis were discussed in this review: one patient presented with encephalopathy; the other patient with acute hemorrhagic necrotizing encephalopathy. And third patient presented with viral encephalitis succeeding COVID-19 vaccination.

Introduction

Coronavirus disease 2019 was declared as a pandemic virus due to COVID-19 cases recorded in many countries. Mainly, the virus of SARS-CoV-2 causing coronavirus disease by infecting the human upper respiratory tract, causing acute respiratory distress syndrome (ARDS) [1, 2]. Over the days, like SARS-CoV and MERS-CoV, the SARS-CoV-2 have also been identified to cause illnesses outside the respiratory tract, gastrointestinal symptoms [3] and nervous system NS. Viruses can enter the NS through the hematogenous or neuronal retrograde route, and infect target cells, neurons [4]. The NS, a system of involved cellular and molecular interactions, sustains life and orchestrates homeostasis.

———— *Corresponding author at: Department of Biology, College of Science for women, University of Babylon, Babylon, Iraq;

ORCID:<https://orcid.org/0000-0002-5368-2127>

E-mail address: nadia.tawfiq@uobabylon.edu.iq

The NS is not protected to severe, tenacious, or dormant viral contagions, that causing some neurological disease. Viral encephalitis is the most prevalent disease known to NS infection. Recently, two studies reported a possible complication of SARS-CoV-2 presence of within the human NS, mainly encephalopathy. Physical examination and medical history can be used to diagnose encephalopathy, such as brain imaging Magnetic Resonance Imaging (MRI) and Computed Tomography (CT) images, which can show any swelling of the brain, cerebrospinal fluid (CSF), in which any changes in this fluid can indicate infection and tenderness in the brain. Electroencephalogram (EEG) records the brain's electrical activity, in which certain abnormal patterns may indicate a diagnosis of encephalitis. In addition, biomedical tests such as blood tests, urine tests, or swab from the throat can be shown for viruses or other infectious causes.

Possible mechanisms of brain diseases by SARS-CoV-2

In respiratory system, a SARS-CoV-2 infection may cause a nasal epithelium disorder, which also causes a large number of viruses to be released from the lower side to the epithelium barrier and reach the bloodstream or lymph and spread to other tissues, including the brain. Human coronavirus HCoV has been found a pass through the neuroepithelium and increase access to the olfactory bulb (OB) and eventually to other regions of the brain[5]. Therefore, SARS-CoV-2 could use the identical way to enter the NS, as shown in Fig 1. On the other hand, SARS-CoV has been found to infect myeloid cells [6] to influence the inborn protection and to distribute to other tissues, counting the NS. Therefore, SARS-CoV-2 could use the alternative route (hematogenous) to penetrate the NS.

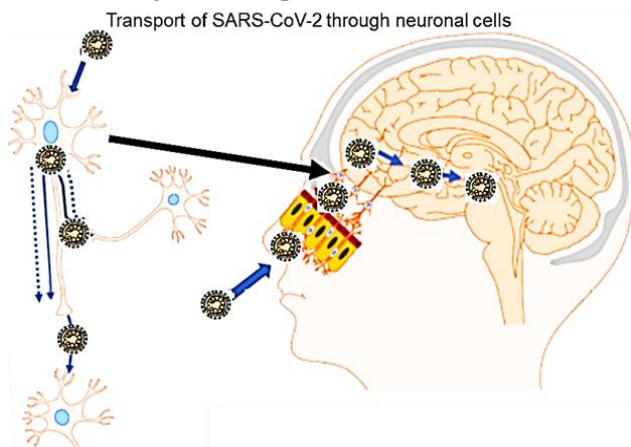


Figure 1. Possible mechanisms of brain diseases by SARS-CoV-2 through the neuroepithelium and increase access to regions of the brain.

Human SARS-CoV-2 in the NS: conceivable related neurological pathologies

Since neurogenic possible of virus types in humans and animals, it is often suggested that a possible correlation exists among the attendance of human coronaviruses everywhere, causing human neurological diseases over the years [6]. It is now found that SARS-CoV-2 is not always narrowed to the upper respiratory tract and that they can enter the NS. In the next sections, two cases of patients with encephalopathy who were diagnosed with COVID-19 were discussed.

Case 1: Potential encephalopathy

The first COVID-19 case is a 74-year-old male diagnosed with encephalopathy [7]. The male was a severed alteration in mental status that requires a neurologist consultant. The diagnosis consisted of an CT image of the head, and EEG of the male. The CT scan displayed no severe irregularities with the occurrence of an area of encephalomalacia in the left chronological region of the head. EEG showed binary deceleration and

principal deceleration in the left temporal part of head with abruptly defined surfs.

Case 2: Potential acute necrotizing encephalopathy (ANE)

The second case is a female airline worker with COVID-19 diagnosed with ANE [5]. Head tomographs confirmed symmetric hypoattenuation inside the two-medial thalamus with standard CT angiography and CT venogram tomography.

Case 3: Potential encephalitis following COVID-19 vaccination

A case of patient after COVID-19 vaccination diagnosed with encephalitis [8]. The female of 65-year-old was a severed alteration in mental status that requires a neurologist consultant. However, the case was unable to conclude whether receiving the COVID-19 vaccine was the reason of encephalitis. On the other hand, other cases [9], [10], [11], [12], [13], [14], [15] suggested that the encephalitis developed after receiving COVID-19 vaccination.

Discussion

Human SARS-CoV-2 pathogens could be associated with the triggering or the exacerbation of several neurological disorders. Recently, a review of [16] suggested worldwide distribution and multifactorial pathogenic mechanisms of viral encephalitis associated with COVID-19, as shown in Fig.2.

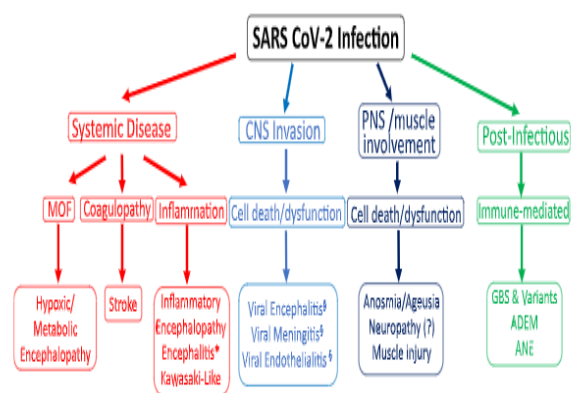


Figure 2. Possible mechanisms of SARS-CoV-2 neuropathogenesis [16].

On the other hand, Chen *et al.*[17] outlined three potential mechanisms of SARS-CoV-2 invasion into the CNS (Fig. 3). Started with infection of the olfactory epithelium, then transport through axonal that enables viral reaches CNS complete the blood or lymphatic system.

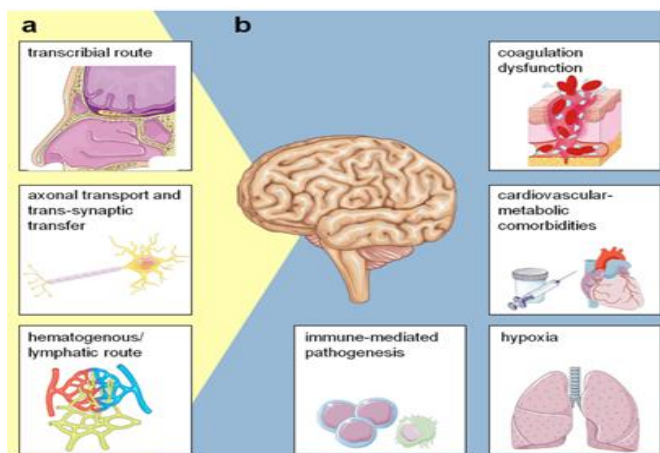


Figure 3. Possible mechanisms of SARS-CoV-2 neuropathogenesis [17].

Conclusion

Wellbeing care breadwinners should be conscious that COVID-19 patients can have encephalopathy during hospitalization. This encephalitis should be accompanied by the recognition of SARS-CoV-2 in cerebrospinal fluid by Real-Time Polymerase Chain Reaction (RT-PCR).

Funding Sources

No any external funding received for this work.

Notes

None.

Acknowledgment

None

Abbreviations

COVID-19, Coronavirus disease 2019; NS, nervous system; ANE, acute necrotizing encephalopathy.

References

- [1] Jebril, N. (2020a). "World Health Organization Declared a Pandemic Public Health Menace: A Systematic Review of the Coronavirus Disease 2019 COVID-19". Available at SSRN: <https://ssrn.com/abstract=3566298>.
- [2] Jebril, N. (2020b). "Distinguishing Epidemiological Curve of Novel Coronavirus Disease (COVID-19) Cases in Iraq: How It Does not Follow the Epidemic Curve of China". Available at SSRN: <https://ssrn.com/abstract=3571889> or <http://dx.doi.org/10.2139/ssrn.3571889>
- [3] Chan, J. F.-W. Yuan, S., Kok, K.-H., To, K. K.-W., Chu, H., Yang, J., Xing, F., Liu, J., Yip, C. C.-Y. & Poon, R. W.-S. (2020). "A familial cluster of pneumonia associated with the 2019 novel coronavirus indicating person-to-person transmission: a study of a family cluster". *Lancet*. 395(10223):514-523.
- [4] Bale, J.F. (2015). "Virus and Immune-Mediated Encephalitis: Epidemiology, Diagnosis, Treatment, and Prevention". *Pediatr. Neurol.*, 53: 3–12.
- [5] Desforges, M.; Coupanec, Le; Dubeau, A.; Bourgouin, P. (2020). "Human Coronaviruses and Other Respiratory Viruses: Underestimated Opportunistic Pathogens of the Central Nervous System?". *Viruses*. 12(1): 14-20
- [6] Spiegel, M. and Weber, F. (2006). "Inhibition of cytokine gene expression and induction of chemokine genes in non-lymphatic cells infected with SARS coronavirus". *Virol. J.* 3(17):23-32.
- [7] Filatov, A.; Sharma, P. and Hindi, F. (2020). "Neurological Complications of Coronavirus Disease (COVID-19): Encephalopathy". *Cureus*. 12(3):4154, 2020,e7352. DOI 10.7759/cureus.735.
- [8] Kobayashi, Y.; Karasawa, S.; Ohashi, N. and Yamamoto, K. (2022). "A case of encephalitis following COVID-19 vaccine". *Journal of Infection and Chemotherapy*, 28(7): 975-977.
- [9] Gao, J.J.; Tseng H.P., and Liu, C.H. (2022). "Acute encephalitis after COVID-19 vaccination: A case report and literature review". *Human Vaccines & Immunotherapeutics*, 18(5): 2082206.
- [10] Shin, H.R.; Kim, B.K.; Lee, S.T. and Kim, A. (2022). "Autoimmune encephalitis as an adverse event of COVID-19 vaccination". *Journal of clinical neurology (Seoul, Korea)*, 18(1): 114-118.
- [11] Zlotnik, Y.; Gadoth, A.; Abu-Salameh, I.; Horev, A.; Novoa, R. and Ifergane, G. (2022). "Case report: anti-LGI1 encephalitis following COVID-19 vaccination". *Frontiers in immunology*, 12: 5749-5753.
- [12] Vences, M.A.; Araujo-Chumacero, M.M.; Cardenas, E.; and Urrunaga-Pastor, D. (2022). "Autoimmune encephalitis after BBIBP-CorV (Sinopharm) COVID-19 vaccination: a case report". *BMC neurology*, 22(1): 1-4.
- [13] Fernandes, J.; Jaggernauth, S.; Ramnarine, V.; Mohammed, S.R.; Khan, C.N.; Panday, A. and Khan, C. (2022). "Neurological conditions following COVID-19 vaccinations: chance or association?". *Cureus Journal of Medical Science*, 14(2):23-33.

- [14] Flannery, P.; Yang, I.; Keyvani, M. and Sakoulas, G. (2021). "Acute psychosis due to anti-N-methyl D-aspartate receptor encephalitis following COVID-19 vaccination: a case report". *Frontiers in Neurology*, 12: 764197.
- [15] Asioli, G.M.; Muccioli, L.; Barone, V.; Giacomozzi, S. and Brutto, M. (2020). "Anti-LGI1 encephalitis following COVID-19 vaccination: a case series". *Journal of Neurology*, 269(11): 5720-5723.
- [16] Koralnik, J.; Igor and Tyler Kenneth, L. (2020). "COVID- 19: a global threat to the nervous system." *Annals of neurology*, l.88(1):1-11.
- [17] Xiangliang, C.; Laurent, S.; Schweitzer, F. and Warnke, C. (2021). "A systematic review of neurological symptoms and complications of COVID-19." *Journal of neurology*, 268: 392-402.

التهاب الدماغ الفيروسي المرتبط بـ COVID والتطعيم التالي لـ COVID-19: مراجعة الأدبيات وثلاث حالات

نادية محمود توفيق جبريل^{1,2}، علي عباس هاشم الموسوي^{3,4}، جارس بينكارت²

¹ قسم علوم الحياة ، كلية العلوم للبنات ، جامعة بابل ، العراق.

² كلية العلوم البيولوجية والبحرية ، جامعة بليموث ، دريك سيرك ، بليموث PL4 8AA ، المملكة المتحدة

³ استشاري جراحة المخ والأعصاب زمالة الكلية الملكية للجراحين في كلاسكو ، زمالة الكلية الملكية للجراحين ، زميل الكلية الملكية للجراحين ، FACS ، FIBMS ، جامعة بابل ، بابل ، العراق.

⁴ قسم جراحة المخ والأعصاب ، كلية طب حمورابي ، جامعة بابل ، بابل ، العراق

nadia.tawfiq@uobabylon.edu.iq

الخلاصة:

يصيب الفيروس التاجي المرتبط بالمتلازمة التنفسية الحادة الوخيمة (SARS-CoV-2) الجهاز التنفسي العلوي للإنسان ، مما يتسبب في مرض فيروس كورونا 2019 (COVID-19) مع أعراض متلازمة الضائقة التنفسية الحادة (ARDS). ومع ذلك ، في الفئات السكانية المعرضة للإصابة ، مثل الأفراد الذين يعانون من ضعف المناعة وكبار السن ، تتطور الأعراض إلى أمراض أكثر حدة (مثل التهاب الرئوي). أكدت البيانات الواردة في الدراسات العصبية أن SARS-CoV-2 له القدرة على إصابة الجهاز العصبي، حيث يمكن أن ينتشر من الجهاز التنفسي إلى الجهاز العصبي (NS) ، مما يسبب التهاب الدماغ. بالمقارنة مع فيروسات كورونا البشرية الغازية ، قد يؤدي السارس-2 CoV إلى تلف الجهاز العصبي ، مما يسبب أمراضاً عصبية. يمكن لمسببات الأمراض البشرية الانتهازية SARS-CoV-2 أن تتوافق مع إثارة أو تفاقم العديد من الاضطرابات العصبية التي لا تزال مسبباتها غير مفهومة جيداً. في هذه المراجعة ، تم توضيح تفاصيل حول فيروسات كورونا البشرية التي تم ربطها بإمكانية الإصابة بمرض في الجهاز العصبي. تمت مناقشة حالتين من حالات التهاب الدماغ الفيروسي في المرضى الذين تم تشخيص إصابتهم بـ COVID-19 في هذه المراجعة: مريض مصاب بالاعتلال الدماغية. المريض الآخر المصاب باعتلال دماغي نزفي حاد. والمريض الثالث أصيب بالتهاب الدماغ الفيروسي بعد التطعيم بلقاح COVID-19

الكلمات المفتاحية: COVID-19 ، الجهاز العصبي ، التهاب الدماغ ، فيروسات كورونا البشرية ، الغزو العصبي ، العدوى الفيروسية التنفسية ، SARS-CoV-2.